

Lesson number seven : Anatomical directional terms :

- **Superior** : toward the head (upper or above).
- **Inferior** : toward the feet (lower or below).

Ex : the heart is located superior to the hip.

Ex : the hip is located Inferior to the heart.

- **Anterior** : further to the front (in front of)

- **Posterior** : further to the back (in back of)

Ex : sternum is anterior to the heart.

Ex : the heart is posterior to the sternum.

- **Medial** : toward the midline of the body (closer to midline).

- **Lateral** : toward the side of the body (further from midline).

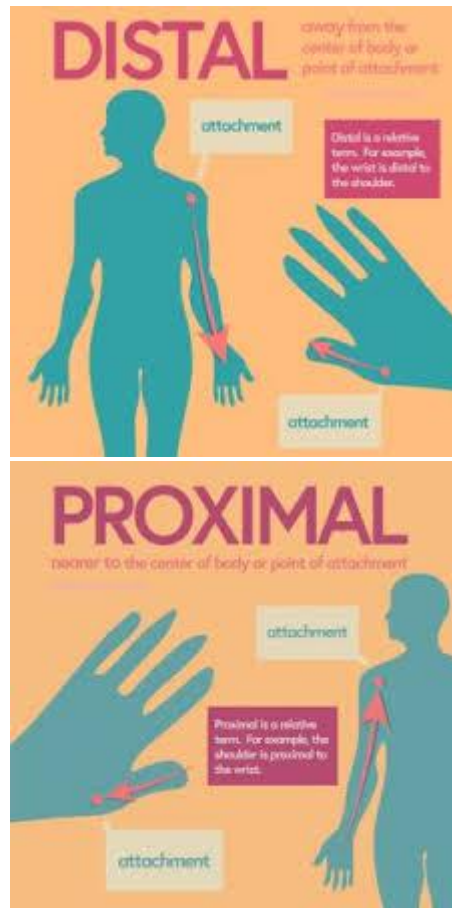
Ex : The heart is medial to the lungs.

Ex : The lungs is lateral to the heart.

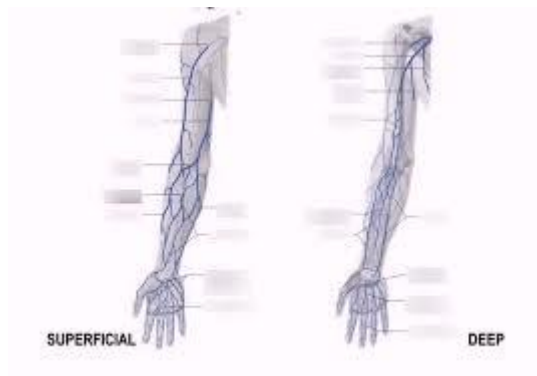
- **Proximal** : closer body in limb.

- **Distal** : further from body in limb.

Ex :



- **Superficial** : shalow (close to surface).
- **Deep** : away from surface



Ex :